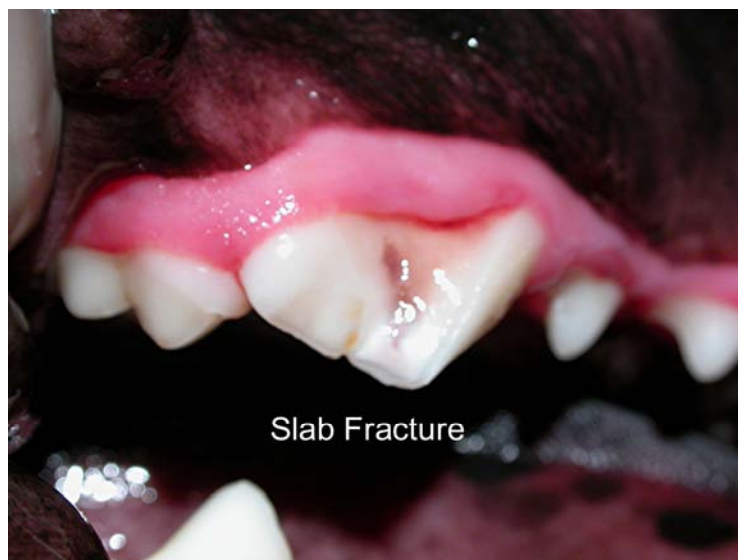

CASE OF THE MONTH (April 2009)

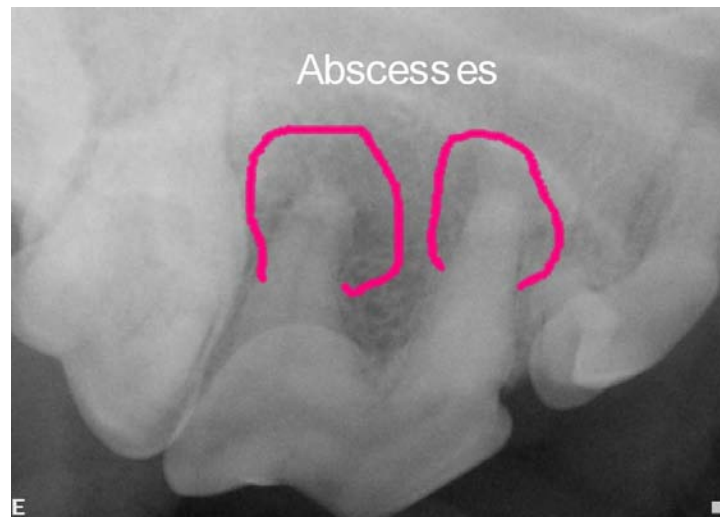Signalment and History:

A five year old neutered male Shar Pei presented for a routine dental prophylaxis. The patient was examined while awake, but was less than cooperative and no obvious pathology was found. I emphasized to the owner that “the real exam begins under anesthesia” and explained that we might find oral pathology upon closer examination.

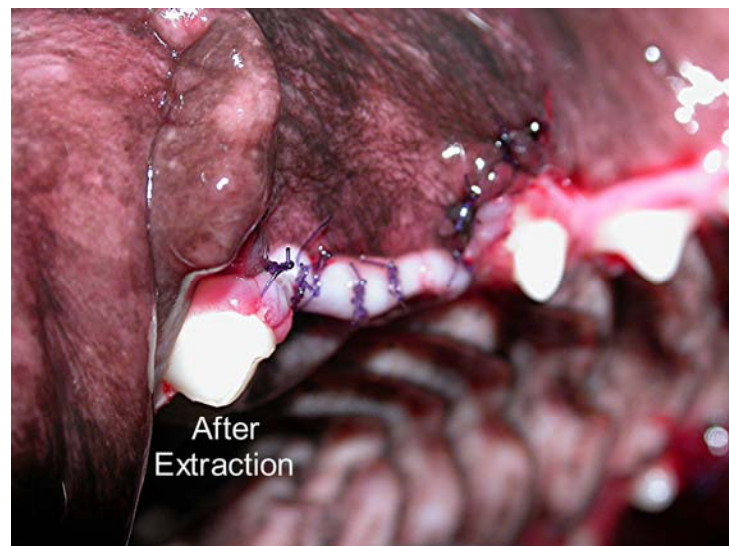Procedures: The patient was placed under general anesthesia for a thorough exam and dental charting. Stage one periodontal disease was present throughout the oral cavity and we planned to treat this condition with a thorough prophylaxis. We also found a slab fracture of the right maxillary 4th premolar. There was no direct pulp exposure, but the enamel had been fractured away, exposing the dentin.



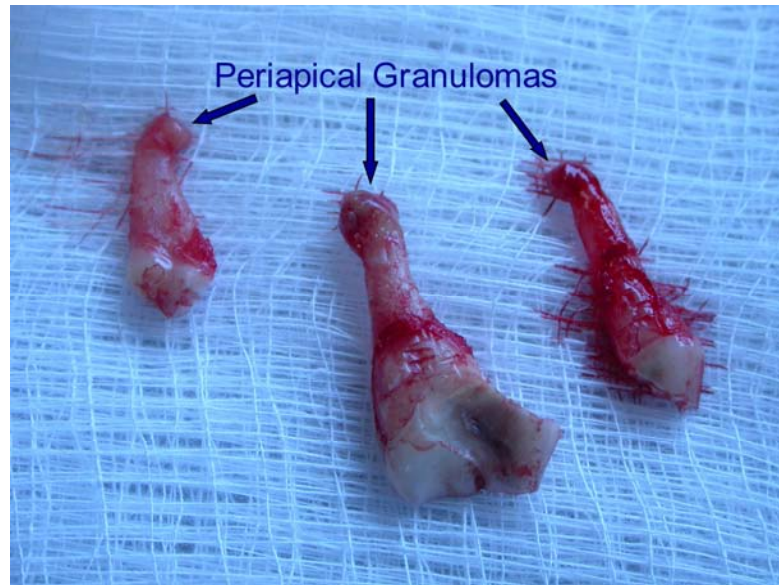
We took an intraoral radiograph of this tooth to evaluate its health and formulate a treatment plan. This radiograph showed periapical lucencies on the mesiobuccal and distal roots.



This tooth was suffering from severe endodontic infection; therefore we had two treatment options: extraction or root canal therapy. The owner elected extraction.



This tooth has three roots, requiring a surgical extraction. The surgical flap was closed with 4-0 Monocryl. Inspection of the extracted roots showed the periapical granulomas which were responsible for the periapical lucencies noted on the radiograph.



Discussion:

A couple of lessons can be gleaned from this simple case. First, “the real exam begins under anesthesia.” When examining a patient that is awake, it is very easy to overlook oral pathology, even if the patient is cooperative. A complete assessment simply cannot be made without probing and a close examination of each tooth in the mouth.

For this reason, it is important to get a phone number from the owner in case unexpected pathology is found. The owner can then be contacted with the complete evaluation and perhaps a revision of expected cost.

Another important lesson involves the type of fracture seen in this case. It is obvious that a fracture with direct pulp exposure will lead to bacterial invasion into the pulp of the tooth. This results in pulpitis, pulp necrosis, and abscess of the tooth.

In this case we had no direct pulp exposure. The enamel was removed, exposing the next layer, the dentin. Dentin is a porous material much like a sponge. Each square millimeter of dentin contains 30-40,000 dentinal tubules, each communicating with the pulp of the tooth. When these tubules are exposed by fracturing away the enamel, bacteria can easily migrate through the tubules into the pulp of the tooth. The result is the same as with a direct pulp exposure. So if we see a fracture with dentin exposure, we must radiograph the tooth to formulate an effective treatment plan.

COMMUNITY ANIMAL HOSPITAL

John A. Koehm, D.V.M., F.A.V.D.

Fellow of the Academy of Veterinary Dentistry

4871 Summit Ridge Drive

Reno, NV 89523

(775)-746-0333